


PATIENT

Abby McCready

PRESENTING CLINICAL SIGNS

History: Last week – thoracic auscultation nsf. Over the weekend she started panting, becoming PU/PD, she had a urinary accident in the house which is unlike her. Grade 4/6 heart murmur heard with increased respiratory rate.

SPECIES

Canine

-Current medications: k-citrate, Hydrochlorothiazide, Tacrolimus/cyclosporin eye drops.

-Abnormal PE/Chem/CBC/UA Results: Slight elevation in ALT and Urea - otherwise no concerns.

-CXR report: Heart is enlarged with reduced lung field.

BREED

Shih Tzu

ELECTROCARDIOGRAPHIC FINDINGS *Note: Single lead ECGs are evaluated as a rhythm strip. Morphology/MEA cannot be definitively commented on.

A single lead ECG is available; 25mm/s, 20mm/mV. Dramatic motion artifact throughout.

SEX

Female Spayed

The average heart rate is 130bpm (range 115-150bpm). The rhythm is sinus in origin, with a p for every QRS complex and vice versa. The P and QRS morphologies are positive. No ectopic beats, pauses or other dysrhythmias observed.

ECG diagnosis: Normal sinus rhythm with respiratory variation.

AGE

12 years

ECHOCARDIOGRAM FINDINGS

2D, m-mode, color flow and doppler imaging is available. Mild diffuse thickening of mitral valve leaflets with no prolapse into the left atrial lumen. Mild anterior-directed mitral regurgitation with mild left atrial dilation. Elevated MR velocity. Normal LV diameter with adequate myocardial function. Global LV hypertrophy (0.9cm). The tricuspid valve appears normal with no tricuspid regurgitation. Normal right atrial and ventricular diameter and morphology indicating no overt evidence of pulmonary arterial hypertension. The pulmonic and aortic valves are normal in morphology and mobility. Normal pulmonic and aortic outflow velocities with laminar flow. No obvious aortic or pulmonic insufficiency. No pericardial or pleural effusion noted. No obvious cardiac masses.

WEIGHT

11.8lbs

INTERPRETED BY

 Maggie Machen Lamy,
 DVM DACVIM
 (Cardiology)

CARDIAC CHART
IMAGING PERFORMED BY

Crystal Hill, RVT

CANINE CARDIAC PARAMETERS	MR VMAX (m/s)	TR VMAX (m/s)	LA/AO (Boon method)	LA/AO (Heart Base; Swe)	FS (%)	EF (%)	EPSS (cm)
NORMAL PARAMETER	4.5-5.5	<2.7	1.3	<1.6	28-40	40-100	<0.6
PATIENT	6.8	NA	1.0	1.0	50	81	0.18
CANINE CARDIAC PARAMETERS	HR (BPM)	AV VMAX (m/s)	PV MAX (m/s)	BODY WEIGHT (kg)	LA 2D short axis Base view (cm)	LVIDd Avg; 2D and m-mode short axis (cm)	LVIDs Avg; 2D and m-mode short axis (cm)
NORMAL PARAMETER	50-100	0.7-1.7	0.7-1.6	BELOW	BELOW	BELOW	BELOW
PATIENT	NM	1.2	1.1	5.35	1.0	2.0	1.0
*Normal chamber parameters expressed as a mean value (SD)				3	1.27 (5.3)	2.46 (2.46)	1.36 (5.5)
BODY WEIGHT DEPENDENT PARAMETERS				5	1.40 (4.5)	2.74 (5.2)	1.60 (4.7)
*Note: All measurements based upon multi-modal images and methods. An average value is reported.				10	1.50 (3.8)	3.27 (3.5)	2.06 (3.1)
				15	1.83 (2.0)	3.71 (2.4)	2.43 (2.1)
				20	2.02 (1.9)	4.14 (2.2)	2.80 (2.0)
				25	2.18 (2.4)	4.48 (2.9)	3.10 (2.5)
				30	2.33 (3.3)	4.83 (3.9)	3.39 (3.4)

 Adapted from June Boon, Veterinary Echocardiography, 1998
 Rishniw M and Hollis NE, J Vet Intern Med 2000; 14:429-435

INVOICE

21832

DATE

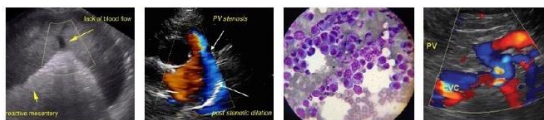
11/2/21

HOSPITAL NAME

 Snelgrove Veterinary
 Services

REFERRING VET

Dr. Ioannou



PATIENT

Abby McCready

Hansson et al, Vet Rad and Ultrasound 2002	35	2.48 (4.3)	5.17 (5.0)	3.69 (4.5)
Bonagura et al. Echocardiography: principles of interpretation, Vet Clin North Am 15:1177, 1995	40	2.62 (5.2)	5.48 (6.1)	3.96 (5.4)
	50	2.88 (7.1)	6.07 (8.3)	4.46 (7.4)

SPECIES

Canine

BREED

Shih Tzu

SEX

Female Spayed

AGE

12 years

WEIGHT

11.8lbs

INTERPRETED BY

Maggie Machen Lamy,
DVM DACVIM
(Cardiology)

IMAGING PERFORMED BY

Crystal Hill, RVT

HOSPITAL NAME

Snelgrove Veterinary
Services

REFERRING VET

Dr. Ioannou

INVOICE

21832

DATE

11/2/21

INTERPRETATION OF THE FINDINGS & FURTHER RECOMMENDATIONS

The cause of the murmur is chronic degenerative valve disease causing mild mitral regurgitation. The left atrium is normal indicating the current risk for complication is low. More concerning is the LV wall dimensions are mildly increased, which may suggest systemic hypertension, pseudohypertrophy or a primary myocardial pathology (unlikely and uncommon). A baseline BP is highly recommended, particularly given the non-specific clinical signs. The LV chamber is also decreased as is the LA dimension, which may suggest pseudohypertrophy; however, lab work is reportedly normal. No additional issues are noted in this study. The ECG is unremarkable with a normal sinus rhythm.

Based upon what is seen here, these findings are considered either incidental or secondary to systemic issues rather than reflecting a primary cause for clinical signs. There is certainly no risk for congestive heart failure at this time and this should be considered unlikely as a cause for respiratory changes. Highly recommend Radiologist review of the films pending further systemic evaluation. Additionally, abdominal evaluation may be useful to screen for ancillary issues (adrenal tumor, etc).

No cardiac medications are clearly indicated. Assessment of progression in the future will help predict long term prognosis, which is highly variable at this stage (B1). Omega fatty acid supplementation and mild salt restriction may be of some long-term benefit. Monitor for development of a cough, labored breathing, exercise intolerance or collapse episodes. If any respiratory signs develop, reevaluate for progressive pulmonary hypertension in this senior predisposed breed.

Pending BP/lab assessment, anesthetic risk is considered mild if needed. Cardiac protective drug choices (opioid/benzodiazepine premedication, propofol or alfaxalone induction, isoflurane gas) are recommended. Pre-oxygenate for 5-10 minutes prior to induction. Monitor for arrhythmias, hypotension, and hypoxia both intra and post-operatively and intervene as necessary. Mild IV fluid restriction is recommended to avoid fluid overload. Avoid heart rate stimulating drugs such as atropine unless clinically indicated.

PLAN

Screening blood pressure is recommended with institution of Amlodipine if persistently >180mmHg. Further internal medicine evaluation is advised in this instance to screen for underlying causes of SHT. Additionally baseline labs are indicated depending on when they were performed.

Recommend conservative monitoring with a recheck echocardiogram in 6 months, sooner if any development of clinical signs.



PATIENT

Abby McCready

SPECIES

Canine

BREED

Shih Tzu

SEX

Female Spayed

AGE

12 years

WEIGHT

11.8lbs

INTERPRETED BY

Maggie Machen Lamy,
DVM DACVIM
(Cardiology)

**IMAGING
PERFORMED BY**

Crystal Hill, RVT

HOSPITAL NAME

Snelgrove Veterinary
Services

REFERRING VET

Dr. Ioannou

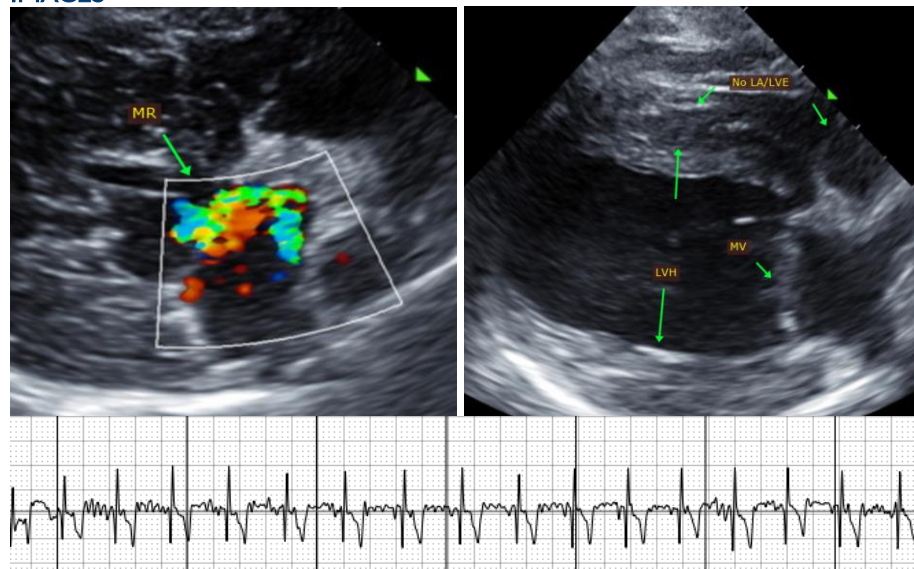
INVOICE

21832

DATE

11/2/21

IMAGES



The information and recommendations provided are based on the images presented by the referring veterinarian. No evaluation can be communicated regarding pathology that was not visible in the image/video clips provided.

Thank you for this referral. This report was generated using transcription software, and minor dictation errors may be present. If the clinical or image interpretation does not parallel your findings or if I can be of any further assistance, please contact me.

Maggie Machen Lamy, DVM
Diplomate of the American College of Veterinary Internal Medicine (Cardiology)
info@sonopath.com